

## Background

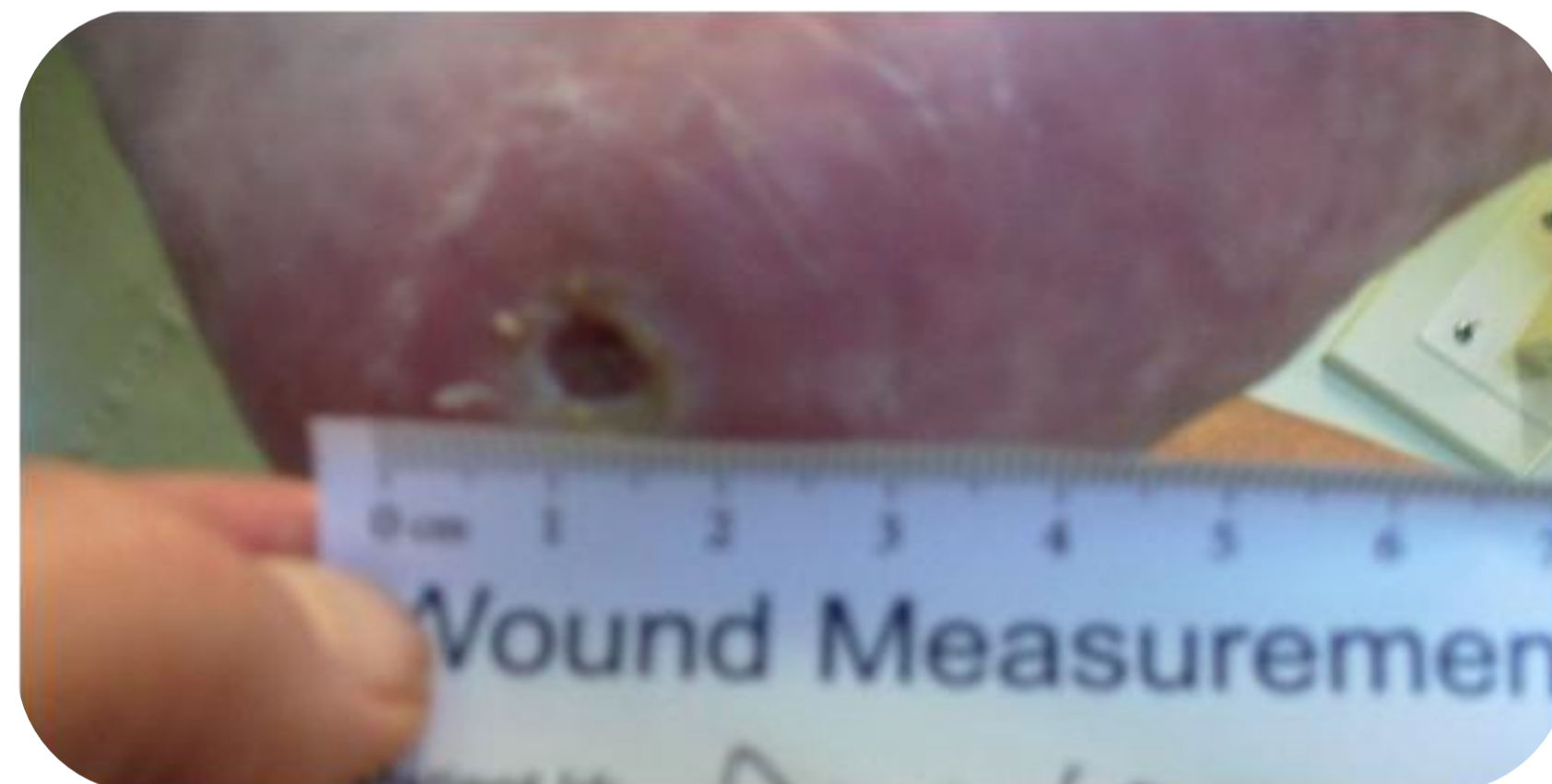Diabetes related foot ulceration is a serious complication of Diabetes mellitus. Diabetes is a risk factor for peripheral artery disease (PAD) and depending on the definition used prevalence rates of 10-40% in the general population of patients with diabetes. Symptoms or signs of PAD can be observed in up to 50% of patients with a diabetic foot ulcer and is a risk factor for poor healing and amputation. PAD and infection are a major cause of lower leg amputation in patients with diabetes (Hinchliffe et al, 2016). The prevention and effective management of wound infection is a high priority for clinicians as infection is a significant problem and can result in delayed healing. Prompt recognition and early management of infection in the diabetic foot is imperative. PHMB has been used for a number of years as an antiseptic agent however it has been recently added to wound care products. PHMB is a mixture of polymers and a synthetic compound which is similar to the antimicrobial peptides (AMP's) found in the majority of living organisms, where they provide an innate immune response. AMP's have a similar mode of action to penicillin and cephalosporin antibiotics (Sorenson et al, 2003). PHMB works by inhibiting bacterial cell metabolism and binding to the bacteria's phospholipid (outer) membrane. (Kingsley & Kiernon, 2012). Advanced Medical Solutions have launched an antimicrobial foam into the ActivHeal range as ActivHeal PHMB foam. The polyurethane pad contains the antimicrobial substance, PHMB, which is released in the presence of exudate and is effective against a broad spectrum of microorganisms that are frequently associated with bacterial colonisation, infection of wounds or wounds at risk of infection. The case study will explore the management of a Neuro-ishaemic diabetic ulcer to the hallux and heel, using the ActivHeal PHMB Foam.

## Method

A 75 year old female patients with type 2 diabetes presented a right foot neuro-ischaemic ulcer to the hallux and heel of 4-6 months duration. The patient had been revascularised and had been diagnosed with Osteomyelitis of the hallux. The patient had been offered surgery but wished to be managed conservatively. A full assessment was undertaken.

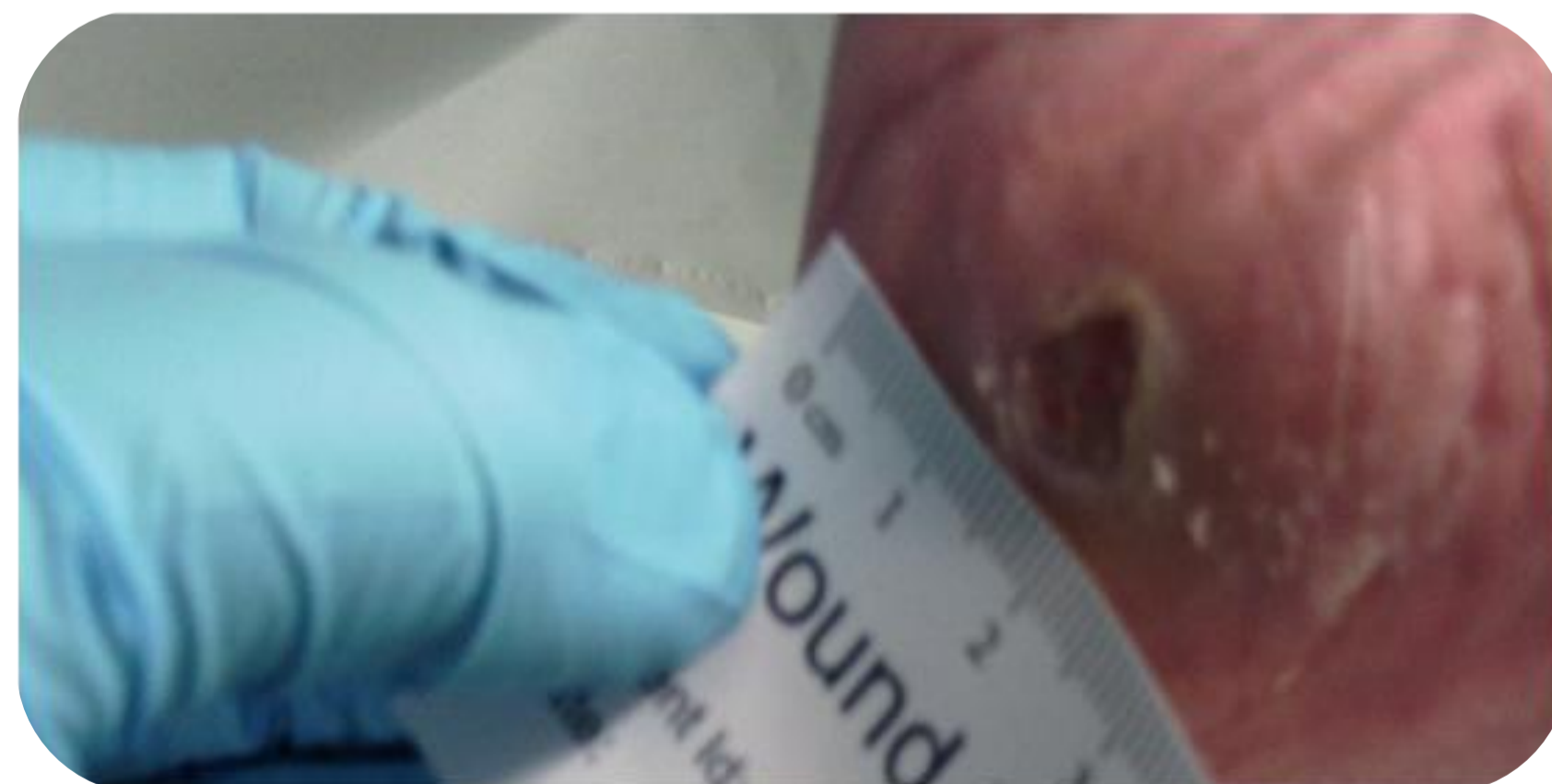
## Results

Wound at initial assessment



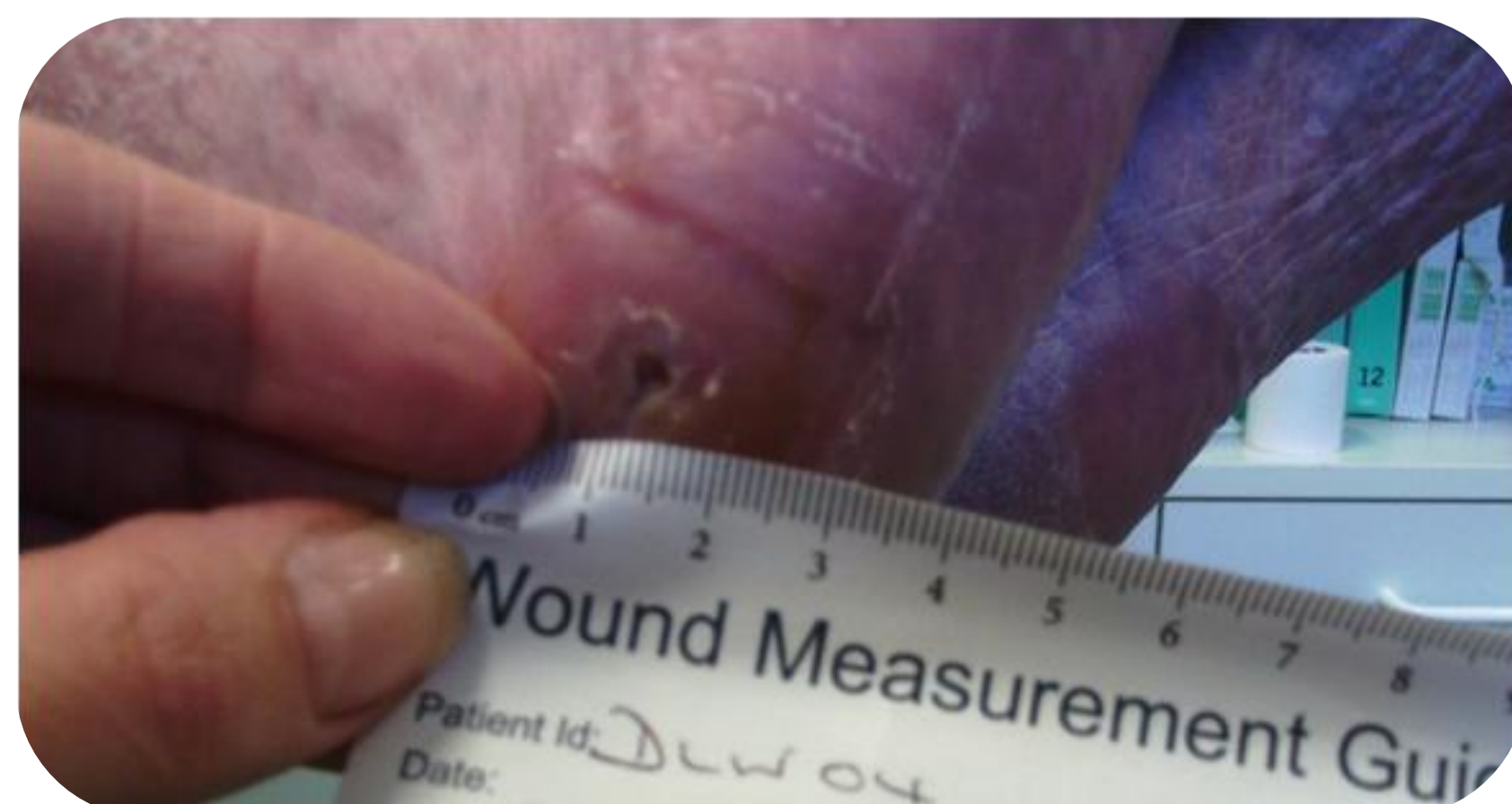- Initial assessment ulcer measured on the heel of 0.5cm diameter and the toe ulcer measured 2.5cm x 2cm and 0.5cm depth. The ulcer had 90% slough and 5% granulation and 5% epithelial tissue and moderate exudate levels. The pain score using a VAS (visual analogue score) was 4. The foot did not show any clinical signs of infection however the patient was at risk of developing an infection. The use of a topical antimicrobial in certain high risk individuals / wounds can also prevent an increase in microbial bioburden and the possible onset of infection (Swanson et al, 2014).The ActivHeal PHMB non adhesive Foam was selected to assist in reducing the risk of wound bioburden, absorb levels of exudate, maintain a moist wound environment, and promote healing.

Wound at week 1



- The wound had made some progress with a reduction in sloughy tissue to 50% and granulating tissue 50%. The wound now measured 0.5cm long, 0.5cm wide and 0.2cm deep. Exudate levels remained moderate and peri wound skin was normal and no signs of maceration. The pain score using a VAS (visual analogue score) was 0. The foot did not show any clinical signs of infection. The dressing regime continued, as moderately exuding.

Wound at week 8



- Significant progress was noted in the wound, with the wound reducing in size and showing wound progression. The wound measured 0.1cm long and 0.1cm wide with 100% granulating tissue. Exudate levels were now low and the peri wound skin remained normal and no signs of maceration. The pain score using a VAS (visual analogue score) was 0. The foot continued to not show any clinical signs of infection. Due to exudate levels now being low the dressing was discontinued and an alternate dressing applied.

## Conclusion

The ActivHeal Foam with PHMB was found to be an appropriate dressing in the management of a neuro-ischaemic diabetic foot ulcer with moderate exudate levels. The dressing produced very positive patient outcomes including: reduced pain increased compliance, ease of single dressing application as opposed to primary in addition to secondary dressing. The correct dressing choice in this case enabled the patient to be managed quickly and effectively without an overly long treatment time. The case study illustrates the importance of a holistic approach when caring for a patient with a challenging wound and ensuring that the correct diagnosis is made based upon a thorough assessment ensuring good clinical outcomes for the patient.

## References

- Hinchliffe,R. Browning,J. Andros,G. Apelquist,J. Boyhoi,E. Fitridge,R. Mills,J. Reekers,J. Shearman,C. Zierler,R. Schaper,N. (2016) Effectiveness of revascularisation of the ulcerated foot in patient's with diabetes and peripheral artery disease: a systematic review. *Diabetes Metab Res Rev.* 32, Suppl 1. 136-146.
- Kingsley,A. Kieron,M. (2012) Suprasorb X and PHMB Made easy. *Wounds UK.* Feb,2012.
- Sorenson, O. Cowland,J. Theilgaard-Monch,K. Liu,L. Ganz,T. Borregaard,N. (2003) Wound Healing and expression of ant microbial peptides, polypeptides in human keratinocytes a consequence of common growth factors. *Journal of Immunol.* 170 (11): 5583-9.
- Swanson,T. Grothier,L. Schultz,G. (2014) Wound Infection made easy. *Wounds International.* Available from: [www.woundsinternational.com](http://www.woundsinternational.com)